

**12****AUTOPSY REPORT**No.  
2020-00797DOE, JOHN  
(LATER IDENTIFIED AS)  
BRYANT, KOBE BEANI performed an autopsy on the body of →  
at the DEPARTMENT OF MEDICAL EXAMINER-CORONERLos Angeles, California on JANUARY 28, 2020 0930 HOURS  
(Date) (Time)From the anatomic findings and pertinent history I ascribe the death to:

(A) BLUNT TRAUMA

DUE TO OR AS A CONSEQUENCE OF

(B)

DUE TO OR AS A CONSEQUENCE OF

(C)

DUE TO OR AS A CONSEQUENCE OF

(D)

OTHER CONDITIONS CONTRIBUTING BUT NOT RELATED TO THE IMMEDIATE CAUSE OF DEATH

MANNER OF DEATH

ACCIDENT

HOW INJURY OCCURRED

COMMERCIAL HELICOPTER CRASH, PASSENGER

*Anatomic Summary:*

- I. Blunt trauma, fatal.
  - A. Blunt trauma of head.
    1. Multiple lacerations of face, scalp, and neck.
    2. Multiple fractures of skull and face.
    3. Evisceration of brain.
  - B. Blunt trauma of chest and abdomen.
    1. Traumatic injuries of neck, left shoulder, and lower abdomen.
    2. Multiple fractures of ribs, spine, and hips.
    3. Evisceration of internal organs.
  - C. Blunt trauma of extremities.
    - A. Multiple fractures of left arm.
    - B. Traumatic amputation of right arm.
      1. Right forearm and hand submitted separately.
    - C. Multiple fractures of the femurs.
    - D. Traumatic amputation of lower extremities.
      1. Both feet recovered.
- II. Postmortem burns.
  - A. Extensively burned skin of head, chest, and abdomen.
  - B. 30% total body surface area burns.
  - C. No soot in trachea or bronchi.



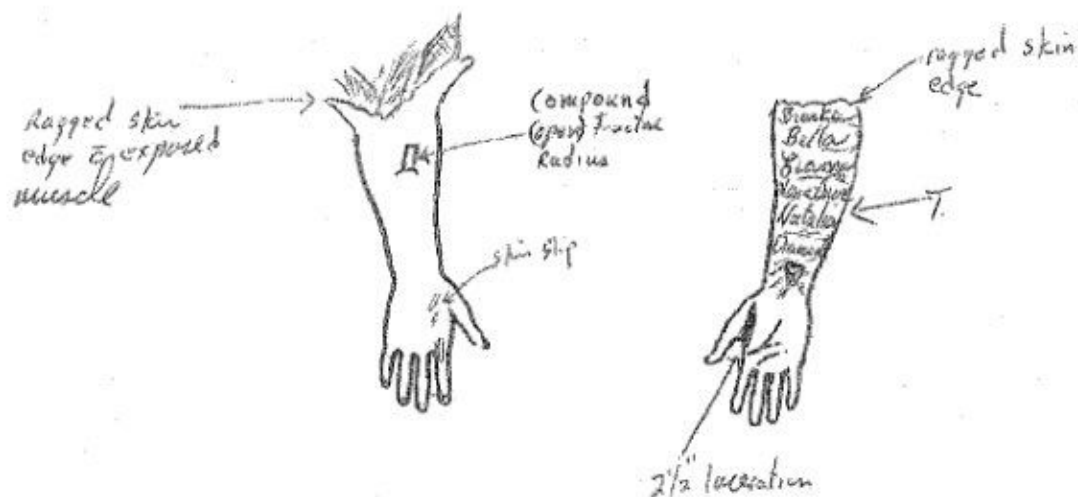
43

## MISCELLANEOUS WORK SHEET

2020-00797

BRYANT, KOBE BEAN  
ACC

SEC

*traumatic amputation  
of right arm*

Date JAN 28 2020

JUAN CARRILLO, M.D.

M.D.

Deputy Medical Examiner